

IMPORTANCE OF THE RED REFLEX TEST IN THE DIAGNOSIS OF CANCER

The photographs below depict the asymmetry or absence of red reflex that can occur in several serious eye conditions, including retinoblastoma. Red reflex examination is essential at post natal, 6-week and routine development examinations, and at any consultation where a parent is anxious about their child's eyes, vision and/or eye appearance.

It is vital to note a child with retinoblastoma may appear well, apart from one or more of the signs noted below. Signs of retinoblastoma can be very subtle and difficult to describe.

Technique In a darkened room sit in front of the child and parent at arm's length; use a good quality halogen light ophthalmoscope set close to zero focussed on the parent's eyes. This shows the test is non-invasive and offers recognition of the normal red reflexes in that particular ethnic group. Then examine the child. The corneal reflex can be checked at the same time. If it is unclear whether the reflex is normal then dilate pupils with drops.

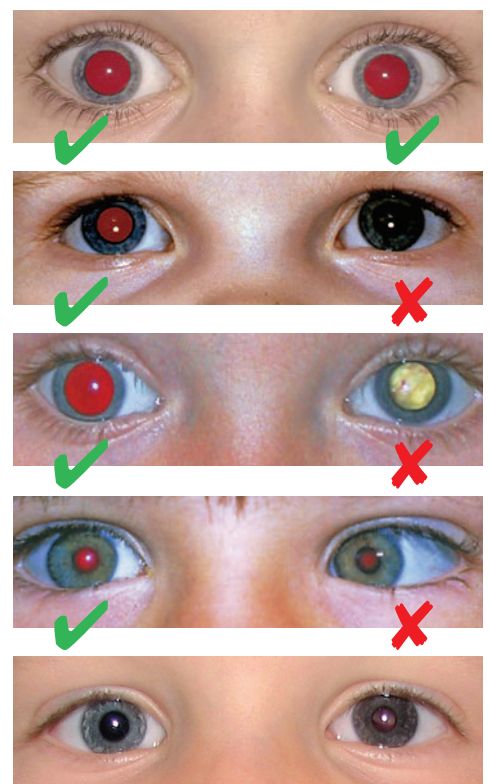
Normal red reflex and corneal reflex The colour and brightness of the red reflex, and the location of the small white corneal reflex, is identical in each eye.

Red reflex absent An absent red reflex in one or both eyes demonstrates serious eye disease (such as cataract or retinoblastoma) requiring urgent referral.

Red reflex is abnormal A red reflex that is the wrong colour or brightness in one or both eyes suggests serious eye disease (such as cataract or retinoblastoma) requiring urgent referral.

Red reflex with a squint A squint is a common indicator of retinoblastoma. Always do a red reflex test on a child presenting with a squint in order to rule out serious eye disease. An abnormal red reflex with squint requires urgent referral.

Other signs of retinoblastoma A change in colour to the iris can occur. This may be in one iris or one part of the iris. One or both eyes can become, red, sore or swollen without any infection. A child may have deterioration in their vision or they may have had poor vision from birth.



A RED REFLEX TEST SHOULD BE DONE FOR ANY OF THE SYMPTOMS ABOVE.

What to do next: If you are unable to confidently rule out retinoblastoma with a red reflex test, NICE guidelines state an urgent referral must be made for children with:

- a white pupillary reflex (leukocoria). Pay attention to parents reporting an odd appearance in their child's eye.
- a new squint or change in visual acuity if cancer is suspected.

- a family history of retinoblastoma and visual problems. (Screening is necessary from birth.)

Urgent referrals should be made to the local ophthalmology department. We recommend you call through to alert them to this case and to find out the speed with which their urgent referrals are seen (in some cases it can be longer than two weeks).

Tel: 020 7377 5578 Email: info@chect.org.uk.

See our website for more information: www.chect.org.uk

This poster was produced by the Childhood Eye Cancer Trust (CHECT) Registered Charity No. 327493.

